

Correspondence

Low-Cost Equipment for Diagnosis and Management of Endemic Scabies Outbreaks in Underserved Populations

TO THE EDITOR—Scabies is a skin parasitosis caused by *Sarcoptes scabiei* var *hominis* and represents a global health problem. Neglected and missed diagnoses for scabies may result in endemic outbreaks, significantly increased economic burden, and considerable morbidity [1]. Scabies diagnosis is traditionally based on microscopic examination of samples obtained by skin scraping. This labor-intensive method provides good specificity, but repeated scrapings may be necessary.

Videodermoscopy is a noninvasive tool useful for early diagnosis of melanoma that has also been shown to be safe and reliable in the diagnosis of scabies [2–4]. Using videodermoscopy, false-negative results are quite rare and false-positive results are nonexistent, as the images obtained are definitive. The roundish translucent body of the mite is clearly visible with visualization of additional anatomical structures of the mite, including legs and rostrum; in most cases, it is possible to visualize real-time movement of the mite inside the burrow. Training for recognition of typical signs (burrows at low magnification; mites/eggs/feces at high magnification) is simple. Videodermoscopy is primarily designed for pigmented lesions, with capability for optimal magnification, high-resolution, and software storage, hence involving significant investment (up to US\$20 000). Recently, low-cost videomicroscopes (VMs) (approximately US\$30) are available for nonmedical use in entomology/botany/microelectronics.

We, therefore, compared a medically marketed videodermoscope (VD) with 2 nonmedical VMs by assessing their reliability in the diagnosis of scabies in a controlled noninferiority clinical trial with independent assessment from dermatologists.

Twenty patients with presumed scabies infestation underwent examination by high-resolution VD (Hirox KH-1300, approximately US\$20 000) as well as 2 low-resolution VMs (Oitez-eScope and Micron Technology USB-Microscope, both approximately US\$30). Images obtained by the 3 systems ($\times 30$ – $\times 150$ magnification) were independently evaluated by 3 dermatologists blinded to the system used.

In all cases, examinations were well tolerated and performed in 10 minutes or less per device. All 3 dermatologists provided definitive diagnoses of scabies based on VD and VM images of burrows, mites, and/or eggs for 15 of the 20 patients, and the 5 remaining patients were negative; this finding was further confirmed by microscopic evaluation of skin scrapings. As the independently determined diagnostic results were identical for all 3 dermatologists, the root mean square deviation of each nonmedically marketed VM compared to the medically marketed VD was equal to zero, establishing the noninferiority of low-resolution VMs compared to high-resolution VD in the

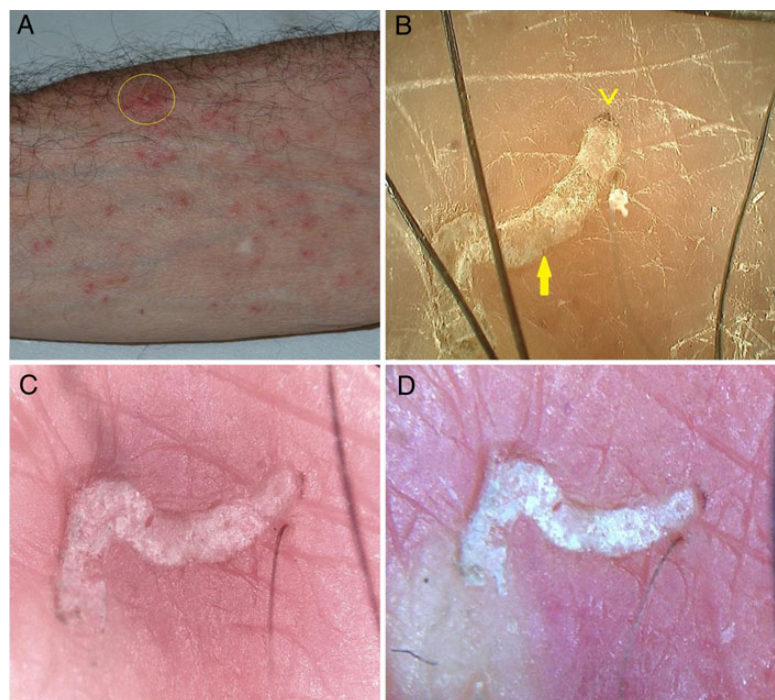


Figure 1. A, Clinical aspect of the right forearm of a patient suspected to have scabies. B, Image of a typical burrow (arrow) obtained by high-resolution videodermoscopy ($\times 150$). The dark triangle on the top (arrowhead) corresponds to the mite's head. C and D, Images of the same field taken using low-cost devices ($\times 150$).

diagnosis of scabies. Direct image comparison showed that all 3 systems enabled an adequate and optimal visualization of the typical signs, although the VD provided a slightly better image definition (Figure 1).

Our findings show that the VMs allowed for a definitive scabies diagnosis, as did the VD. In addition to significantly improved cost-effectiveness in the management of scabies outbreaks, VMs can provide the ability to accomplish rapid noninvasive mass screening, easy posttherapeutic follow-up, and minimization of risks from missed diagnoses. Although study limitations include a small sample size and evaluation of only 1 VD, as both the VD and the VMs provided definitive scabies diagnoses, the chosen sample size appears to be well-justified, particularly in light of the 100% concordance for all 3 dermatologists. The impact of low-cost VMs appears to be significant and cost-effective. In Western countries, scabies infestation occurs in all socioeconomic groups as well as in institutional settings such as hospitals,

nursing homes, long-term-care facilities, prisons, and schools—populations that are considered at “high risk” for outbreaks that may lead to endemic outcomes. Therefore, with an initial affordable investment (no maintenance is required), the costs related to delayed treatment and misdiagnosis, as well as the number of missed work/school days and unneeded medical consultations, are expected to be consistently reduced [5]. Accurate and definitive diagnosis of scabies is crucial in communities experiencing endemic outbreaks where noninvasive techniques and low costs are essential, with particular attention to geographic areas of unmet need, such as underdeveloped countries with tropical and subtropical climates that are even more conducive to fostering scabies infestations.

Note

Potential conflicts of interest. All authors: No reported conflicts.

All authors have submitted the ICMJE Form for Disclosure of Potential Conflicts of Interest. Conflicts that the editors consider relevant to the content of the manuscript have been disclosed.

**Giuseppe Micali, Francesco Lacarrubba,
Anna Elisa Verzi, and Maria Rita Nasca**

Dermatology Clinic, University of Catania, Italy

References

1. Owusu-Edusei K Jr, Chesson HW, Gift TL. The economic burden of pediculosis pubis and scabies infections treated on an outpatient basis in the United States: evidence from private insurance claims data, 2001-2005. *Sex Transm Dis* **2009**; 36:297-9.
2. Micali G, Lacarrubba F, Lo Guzzo G. Scraping versus videodermatoscopy for the diagnosis of scabies: a comparative study. *Acta Derm Venereol* **1999**; 79:396.
3. Zalaudek I, Giacometti J, Cabo H, et al. Entodermoscopy: a new tool for diagnosing skin infections and infestations. *Dermatology* **2008**; 216:14-23.
4. Lacarrubba F, Micali G. Videodermatoscopy and scabies. *J Pediatr* **2013**; 163:1227.
5. Engelman D, Kiang K, Chosidow O. Toward the global control of human scabies: introducing the International Alliance for the Control of Scabies. *PLoS Negl Trop Dis* **2013**; 7:e2167.

Correspondence: Giuseppe Micali, MD, Dermatology Clinic, University of Catania, A.O.U. Policlinico-Vittorio Emanuele, Via Santa Sofia, 78-95123 Catania, Italy (gimicali1@hotmail.it).

Clinical Infectious Diseases®

© The Author 2014. Published by Oxford University Press on behalf of the Infectious Diseases Society of America. All rights reserved. For Permissions, please e-mail: journals.permissions@oup.com.

DOI: 10.1093/cid/ciu826